

Case Series

Soft tissue healing outcomes in dentistry with acellular dermal collagen matrix

Massimo Frosecchi ^{1*}, Nicola De Angelis ²

¹ Studio Dentistico Dott. Massimo Frosecchi, Florence, 50129, Italy

² Studio de Angelis, AQUI Terme, 15011, Italy; n.deangelis74@gmail.com (N.D.A)

* Correspondence: massimofrosecchi@gmail.com

Abstract: Background and objectives: The collagen matrices are widely used for regeneration procedures alone or in combination with other dental regeneration materials. The aim of this work was to evaluate the soft tissue healing with acellular dermal collagen matrix (ADCM) being used in various defects. Materials and Methods: The ADCM - mucoderm[®] was used in peri-implant soft tissue augmentation, hard and soft tissue management in immediate restoration and sealing of extraction socket. For that reason, five patients were retrospectively analysed. Results: The collagen matrix underwent active remodelling into new soft tissue and successful soft tissue healing was observed. Conclusion: The use of mucoderm[®] led to successful soft tissue treatment in various defects.

Keywords: acellular dermal collagen matrix, soft tissue healing, soft tissue augmentation, soft tissue management, extraction socket



Published: 24.06.2022

DOI: <https://doi.org/10.56939/DBR221028f>

Introduction

The dental regeneration biomaterials have been used for regeneration purposes since many years now [1], [2]. They can mainly be classified as biomaterials for hard and soft tissue regeneration [3]. Such materials can be derived from natural (xenogenic, allogenic, autogenic) or synthetic origin and can be divided into granules, blocks, fleeces, barrier membranes and collagen matrices [4].

Nowadays the collagen matrices are mainly used as an alternative for connective tissue grafts [5]–[7]. They consist of collagen, which undergoes complete remodelling into new patient's soft tissue [8], [9]. However, the variations in their production process can significantly alter the clinical outcome [10].

To be more specific, the currently commercially available collagen matrices have certain advantages and disadvantages that questions their successful performance in various indications [11]. For example, the combination of peritoneum derived barrier membrane with fleece to produce collagen matrix such as Mucograft[®] results into faster degradation time if compared to long-time resorbing GBR membrane [12], [13]. This affects the new bone formation in combination with particulate graft material and can possibly influence the successful remodelling of the soft tissue. For that reason, the dermally derived collagen matrices - ADCM attract much more attention these days. They have improved handling and longer lasting degradation time, which in turn provides better conditions for soft tissue healing [8], [14]. AlloDerm SELECT[™] Regenerative Tissue Matrix (RTM) is a human derived ADCM and has been a widely accepted for various soft tissue applications [15]. However, exposed AlloDerm can produce a pungent, necrotic smell that makes the patient uncomfortable, which is most probably due to its human processed tissue manufacturing method [16]. On the other hand, the use of mucoderm[®], a porcine derived dermis that undergoes a multi-step purification process, doesn't show

that problem, has proven as successful to facilitate soft tissue regeneration and undergoes complete remodeling into patient's own tissue in 6-9 months [8], [17].

The aim of this work was to evaluate the soft tissue healing with ADCM - mucoderm® in various indications. To realize that we retrospectively analysed several patients with different defects that were treated with one and same ADCM.

Materials and Methods

Five patients were retrospectively analyzed after being successfully treated with acellular dermal collagen matrix-ADCM (mucoderm®, Botiss biomaterials GmbH, Zossen, Germany) (Table 1). All patients gave their informed consent before the treatment started and all cases were conducted in accordance with the Declaration of Helsinki 2013.

Table 1. Overview of the indications and recorded healing period after treatment

	Indication	Recorded healing period
Patient 1	Peri-implant soft tissue augmentation for pontic	3 months
Patient 2	Hard and Soft tissue management in intermediate restoration in the esthetic area with partial edentulism	15 days, 2 months, 2,5 months
Patient 3	Immediate implantation	7 days, 3 months
Patient 4	Sealing of extraction socket	7 days, 2 months
Patient 5	Sealing of extraction socket	2 months

Patient 1 was 81 years old, nonsmoker normal healthy male. After clinical and radiographic examination of the anatomy, a lost ridge bone and keratinized tissue after tooth extraction was observed (Figure 1a). Non-inflammatory healthy soft tissue with good oral hygiene was detected, allowing the course of treatment to be planned together with the patient. Due to the patient's refusal to use autologous soft tissue grafts, treatment with ADCM after placing of two implants was chosen (Figure 1b). For that reason, mucoderm® was cut in two halves and inserted buccally to increase the soft tissue volume, to decrease soft tissue mobility and obtain a certain degree of new keratinized tissue. Then tension-free wound closure with slightly exposed ADCM area was left (Figure 1c).

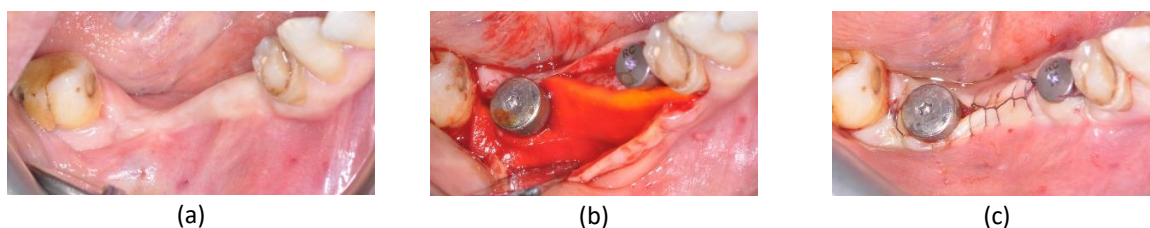


Figure 1. Patient 1: (a) Initial clinical situation; (b) treatment with mucoderm®; (c) tension-free suturing.

In patient 2, a 67-year-old nonsmoker female, the clinical and radiographic examination showed fistula and abscesses which required tooth extraction at position 11 and 21 (Figure 2a). After crestal incision and placement of two implants (Figure 2b), the sockets were preserved with xenograft (cerabone®, botiss biomaterials GmbH, Zossen, Germany) (Figure

2c). Then mucoderm® was used for a coverage of the ridge preservation areas in the central incisors and soft tissue volume augmentation in lateral incisors areas (Figure 2d) before wound closure (Figure 2e).

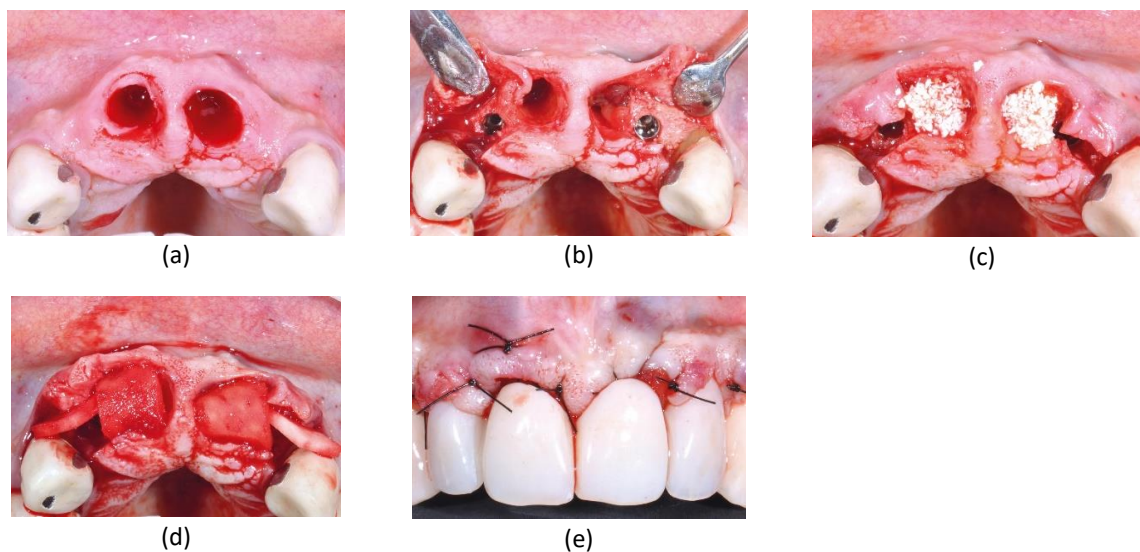


Figure 2. Patient 2: (a) Initial clinical situation; (b) placed implants; (c) socket preservation with cerabone®; (d) coverage and soft tissue management with mucoderm®; (e) wound closure.

The clinical and radiographic examination in patient 3, an 87-year-old nonsmoker female, showed a severe decay of the molar which required tooth extraction before immediate implant placement (Figure 3a, b). For that reason, a flap was prepared, tooth at position 35 was extracted, implants were inserted at position 35 and 34, and the gaps around the implant were filled with bi-phasic synthetic graft (maxresorb®, botiss biomaterials GmbH, Zossen, Germany) (Figure 3c). Then mucoderm® was buccally positioned for soft tissue thickening purpose (Figure 3d). Finally, the area was covered with collagen fleece (collafleece®, botiss biomaterials GmbH, Zossen, Germany) (Figure 3e), which allowed flap adaptation and suturing by leaving the fleece partially exposed (Figure 3f).

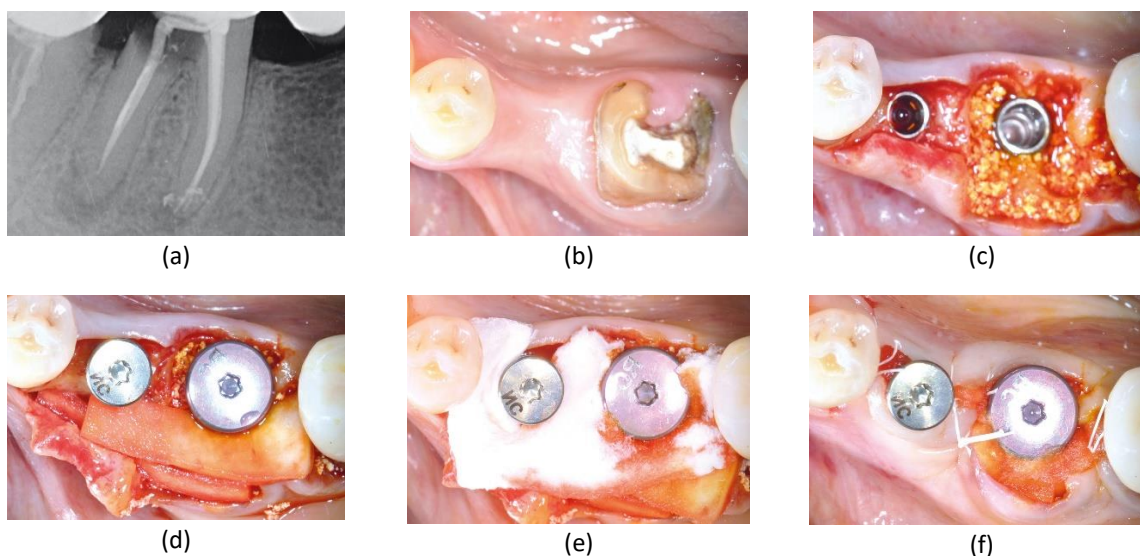


Figure 3. Patient 3: (a) X-ray control; (b) Initial clinical situation; (c) immediate implant placement with maxresorb®; (d) coverage and soft tissue management with mucoderm®; (e) coverage with collafleece®; (f) wound closure with fleece partially exposed.

Patient 4, a 41-year-old nonsmoker male, underwent tooth extraction due to root fracture (Figure 4a). After atraumatic extraction with intact bony walls and leaving favorable socket morphology, the blood clot was stabilized with mucoderm® alone (Figure 4b). Then the socket was further stabilized with a cross-suture by leaving mucoderm® exposed (Figure 4c). Like this, the socket was easily protected and prepared for an early implant placement procedure.

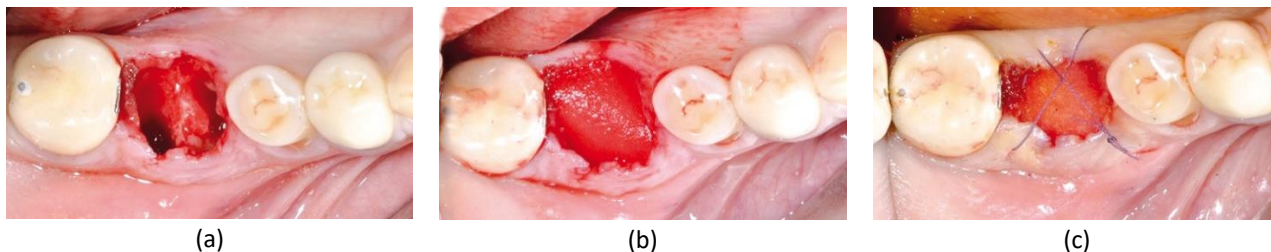


Figure 4. Patient 4: (a) Atraumatic extraction socket; (b) blood clot stabilization with mucoderm®; (c) stabilization by cross-suture.

Patient 5, a 48-year-old non-smoker female, required tooth extraction due endodontic failure of a molar (Figure 5a). Here an atraumatic extraction with intact bony walls was also achieved (Figure 5b). Since favorable alveolar bone defect geometry was present, the blood clot was then stabilized with mucoderm® alone and cross-suture (Figure 5c). This treatment prepared the socket for an early implant placement procedure.

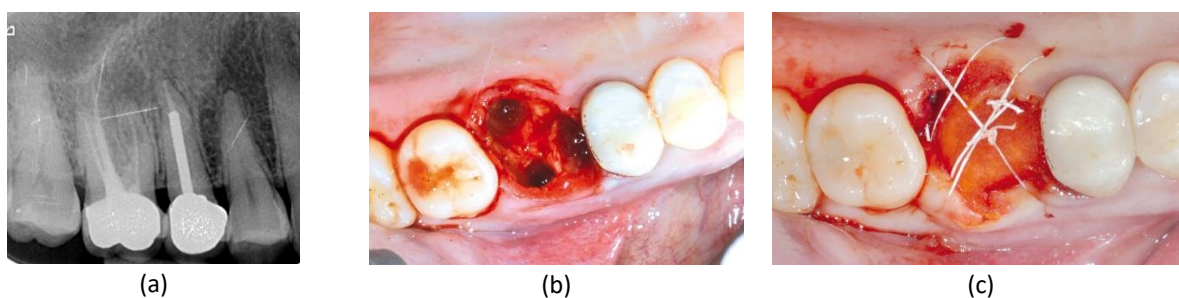


Figure 5. Patient 5: (a) X-ray showing endodontic failure; (b) atraumatic tooth extraction; (c) blood clot stabilization with mucoderm®.

Results

Patient 1 had complication free healing and larger layer of keratinized tissue was observed 3 months after the operation (Figure 6a). Consequently, a standard metal ceramic bridge was placed (Figure 6b) and the X-ray control showed stable tissue for pontic (Figure 6c).

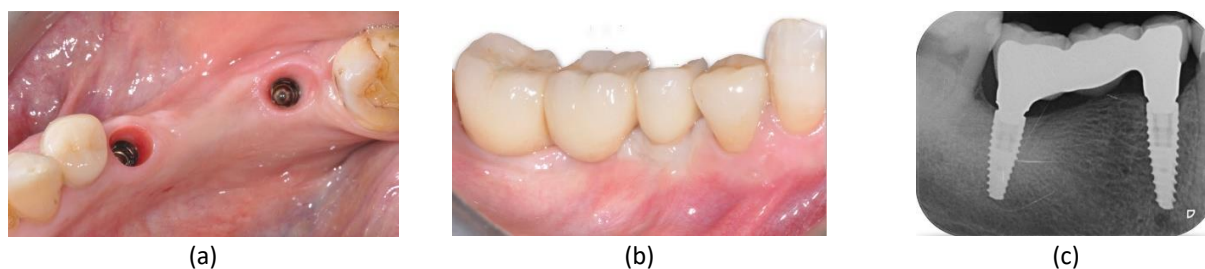

Figure 6. Patient 1: (a) Healing at 3 months post-op; (b) placement of standard metal ceramic bridge; (c) X-ray control.

Patient 2 had successful soft tissue healing after 15 days (Figure 7a, b) and healthy soft tissue situation was also observed after 2 months (Figure 7c, d) and 2,5 months (Figure 7e). The final restoration resulted into high esthetical outcome (Figure 7f).

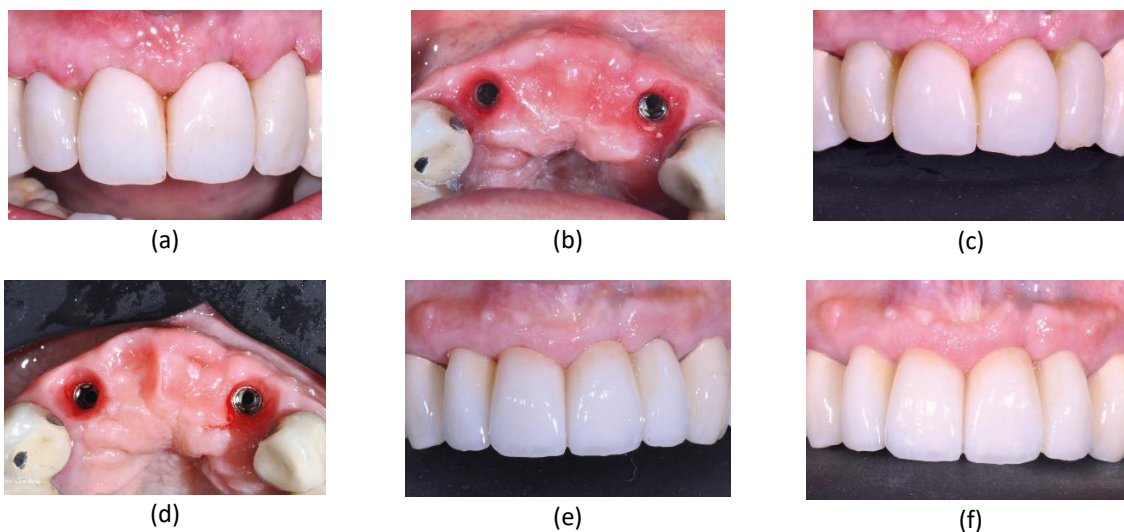


Figure 7. Patient 2: (a) Healing at 15 days post-op; (b) Healing at 15 days post-op, occlusal view; (c) Healing at 2 months post-op; (d) Healing at 2 months post-op, occlusal view; (e) Healing at 2,5 months post-op; (f) Final restoration.

Patient 3 had a very satisfactory soft tissue healing situation at 7 days post-op (Figure 8a). In addition, the soft tissue situation continued to improve within 3 months (Figure 8b). For that reason, final restoration with screw retained zirconium crowns was performed (Figure 8c).

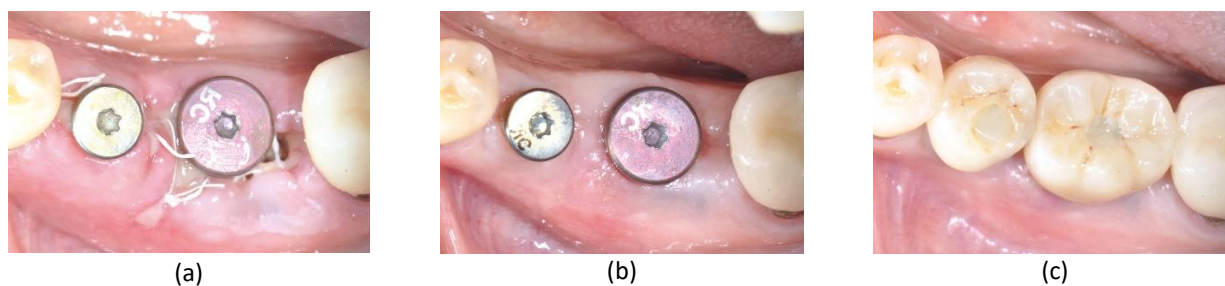


Figure 8. Patient 3: (a) Healing at 7 days post-op; (b) Healing at 3 months post-op; (c) final restoration.

Patient 4 had complication free soft tissue healing on day 7 after the operation (Figure 9a). After 2 months, the patient had healthy soft tissue (Figure 9b), which enabled successful soft tissue conditioning after implant placement and application of the healing cap (Figure 9c).

Patient 5 had healthy soft tissue after 2 months (Figure 10a), which enabled successful implant placement with satisfactory osteointegration and appropriate soft tissue conditioning (Figure 10b, c).

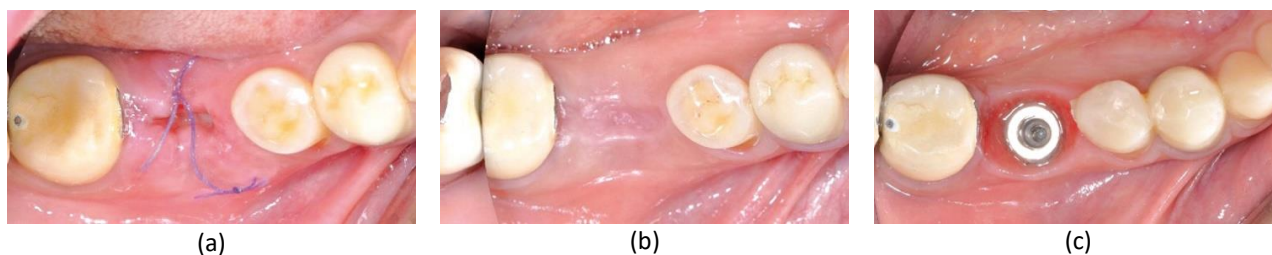


Figure 9. Patient 4: (a) Healing at 7 days post-op; (b) Healing at 2 months post-op; (c) Soft tissue conditioning after implant placement.

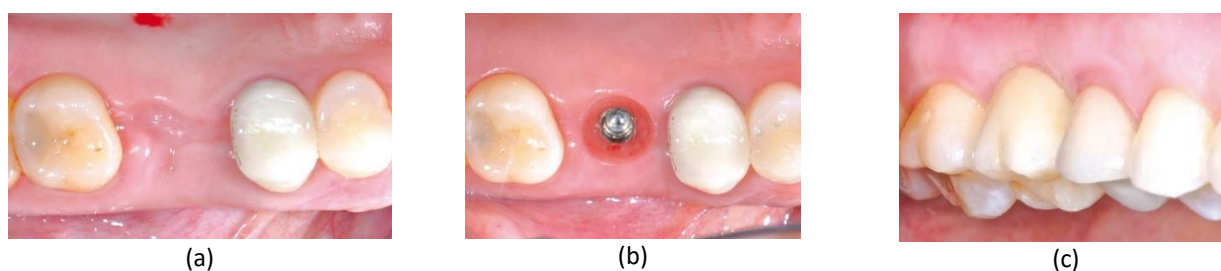


Figure 10. Patient 5: (a) Healing at 2 months post-op; (b) Healing at 1,5 months after implant placement; (c) final restoration.

Discussion

These case series describe successful ADCM - mucoderm® remodeling into new patients' soft tissue. Even though various defects were treated, still a successful soft tissue healing was achieved in all cases.

ADCMs have been used as an alternative for connective tissue grafts and have proven that satisfactory soft tissue healing can be achieved [18]. While many studies focus on the indication itself or the surgical technique, still not many studies focus on the biomaterial properties and their regeneration supporting effect. To be more specific, the combination of short-resorbing collagen barrier membrane and collagen fleece has certain soft tissue healing effect [19]. However, some indications as recession covering require a longer lasting collagen matrix such as ADCM [18], [20]. Here the longer-lasting compact collagen structure enables sufficient scaffold function where early blood vessels can develop [8], [21]–[23]. Once the blood vessels penetrate the ADCM, they can bring in the "life" from within and remodel the matrix [21], [22]. Therefore, a long-lasting soft tissue regeneration result can be achieved [14], [24], [25].

Based on that regenerative mechanism, the dermally derived dense collagen structure could also achieve successful healing in other soft tissue healing indications [14], [26]–[28]. For that reason, we analyzed the application of mucoderm® in peri-implant soft tissue augmentation, hard and soft tissue management in immediate restoration and sealing of extraction socket. Here the compact collagen matrix was remodeled into new patients' soft tissue and successful soft tissue healing was achieved in all cases.

Conclusions

We evaluated the soft tissue healing with ADCM in various defects such as peri-implant soft tissue augmentation, hard and soft tissue management in immediate restoration and sealing of extraction socket. The dense collagen matrix underwent active remodeling into new soft tissue and successful soft tissue healing was observed in all cases. The current

case series is limited to five patients only and more research needs to be done to evaluate the success rate in larger number of patients.

Funding and conflict of interest statement: The authors claim no conflict of interest and no funding or sponsorship was received for this work.

Board review and informed consent statement: In compliance with the Declaration of Helsinki (2013), the patients were informed orally and in written about the planned procedures and were given at least 2 weeks for consideration. The patients had the right to withdraw consent and to interrupt treatment at any time without reprisal. The local authorities allow results publication if these criteria are met.

References

- [1] R. Zhao, R. Yang, P. R. Cooper, Z. Khurshid, A. Shavandi, and J. Ratnayake, "Bone grafts and substitutes in dentistry: A review of current trends and developments," *Molecules*, vol. 26, no. 10. *Molecules*, 2021, doi: 10.3390/molecules26103007.
- [2] H. Ananth, V. Kundapur, H. S. Mohammed, M. Anand, G. S. Amarnath, and S. Mankar, "A review on biomaterials in dental implantology," *International Journal of Biomedical Science*, vol. 11, no. 3. Master Publishing Group, pp. 113–120, Sep. 15, 2015, Accessed: Aug. 08, 2021. [Online]. Available: /pmc/articles/PMC4614011/.
- [3] H. K. Raut, R. Das, Z. Liu, X. Liu, and S. Ramakrishna, "Biocompatibility of Biomaterials for Tissue Regeneration or Replacement," *Biotechnology Journal*, vol. 15, no. 12. John Wiley & Sons, Ltd, p. 2000160, Dec. 01, 2020, doi: 10.1002/biot.202000160.
- [4] B. Trajkovski, M. Jaunich, W. D. Müller, F. Beuer, G. G. Zafiroopoulos, and A. Houshmand, "Hydrophilicity, viscoelastic, and physicochemical properties variations in dental bone grafting substitutes," *Materials (Basel)*, vol. 11, no. 2, Jan. 2018, doi: 10.3390/ma11020215.
- [5] R. H. M. Preidl, S. Reichert, T. V. Coronel, M. Kesting, F. Wehrhan, and C. M. Schmitt, "Free Gingival Graft and Collagen Matrix Revascularization in an Enoral Open Wound Situation," *J. Oral Maxillofac. Surg.*, vol. 79, no. 5, pp. 1027–1037, May 2021, doi: 10.1016/j.joms.2020.12.019.
- [6] K. T. Suzuki *et al.*, "Root coverage using coronally advanced flap with porcine-derived acellular dermal matrix or subepithelial connective tissue graft: a randomized controlled clinical trial," *Clin. Oral Investig.*, vol. 24, no. 11, pp. 4077–4087, May 2020, doi: 10.1007/s00784-020-03280-x.
- [7] S. Vincent-Bugnas, J. Laurent, E. Naman, M. Charbit, and G. Borie, "Treatment of multiple gingival recessions with xenogeneic acellular dermal matrix compared to connective tissue graft: a randomized split-mouth clinical trial," *J. Periodontal Implant Sci.*, vol. 50, no. 2, pp. 1–11, 2020, doi: 10.5051/JPIS.2002400120.
- [8] D. Rothamel *et al.*, "Biodegradation pattern and tissue integration of native and cross-linked porcine collagen soft tissue augmentation matrices - an experimental study in the rat," *Head Face Med.*, vol. 10, no. 1, Mar. 2014, doi: 10.1186/1746-160X-10-10.
- [9] A. Puisys *et al.*, "Clinical and Histologic Evaluations of Porcine-Derived Collagen Matrix Membrane Used for Vertical Soft Tissue Augmentation: A Case Series," *Int. J. Periodontics Restorative Dent.*, vol. 39, no. 3, pp. 341–347, May 2019, doi: 10.11607/prd.4097.
- [10] M. Meyer, "Processing of collagen based biomaterials and the resulting materials properties," *Biomed. Eng. Online*, vol. 18, no. 1, Mar. 2019, doi: 10.1186/s12938-019-0647-0.
- [11] A. Pabst and P. W. Kämmerer, "Collagen matrices: Opportunities and perspectives in oral hard and soft tissue

- regeneration," *Quintessence Int. (Berl)*, vol. 51, no. 4, pp. 318–327, 2020, doi: 10.3290/J.QI.A44149.
- [12] S. Ramalingam *et al.*, "Efficacy of Mucograft vs Conventional Resorbable Collagen Membranes in Guided Bone Regeneration Around Standardized Calvarial Defects in Rats: A Histologic and Biomechanical Assessment," *Int. J. Periodontics Restorative Dent.*, vol. 36, pp. s99–s107, 2016, doi: 10.11607/prd.2277.
- [13] A. Basudan *et al.*, "Efficacy of Mucograft vs Conventional Resorbable Collagen Membranes in Guided Bone Regeneration Around Standardized Calvarial Defects in Rats: An In Vivo Microcomputed Tomographic Analysis," *Int. J. Periodontics Restorative Dent.*, vol. 36, pp. s109–s121, 2016, doi: 10.11607/prd.2261.
- [14] P. Papi, N. Pranno, B. Di Murro, and G. Pompa, "Early implant placement and peri-implant augmentation with a porcine-derived acellular dermal matrix and synthetic bone in the aesthetic area: a 2-year follow-up prospective cohort study," *Int. J. Oral Maxillofac. Surg.*, vol. 50, no. 2, pp. 258–266, Feb. 2021, doi: 10.1016/j.ijom.2020.07.002.
- [15] L. A. Jansen, P. De Caigny, N. A. Guay, W. C. Lineaweaver, and K. Shokrollahi, "The evidence base for the acellular dermal matrix AlloDerm: A systematic review," *Ann. Plast. Surg.*, vol. 70, no. 5, pp. 587–594, May 2013, doi: 10.1097/SAP.0b013e31827a2d23.
- [16] J. B. Suzuki and C. E. Misch, "Periodontal and Maintenance Complications," in *Misch's Avoiding Complications in Oral Implantology*, Elsevier, 2018, pp. 771–826.
- [17] G. G. Zafiroopoulos, A. A. Al-Asfour, M. Abuzayeda, Z. P. Kačarević, C. A. Murray, and B. Trajkovski, "Peri-implant mucosa augmentation with an acellular collagen matrix," *Membranes (Basel)*, vol. 11, no. 9, Sep. 2021, doi: 10.3390/membranes11090698.
- [18] D. L. Rakasevic, I. Z. Milinkovic, S. M. Jankovic, I. A. Soldatovic, Z. M. Aleksic, and N. S. Nikolic-Jakoba, "The use of collagen porcine dermal matrix and connective tissue graft with modified coronally advanced tunnel technique in the treatment of multiple adjacent type I gingival recessions: A randomized, controlled clinical trial," *J. Esthet. Restor. Dent.*, vol. 32, no. 7, pp. 681–690, Oct. 2020, doi: 10.1111/jerd.12624.
- [19] Z. Menceva, O. Dimitrovski, M. Popovska, S. Spasovski, V. Spirov, and G. Petrushevska, "Free gingival graft versus Mucograft: Histological evaluation," *Open Access Maced. J. Med. Sci.*, vol. 6, no. 4, pp. 675–679, Apr. 2018, doi: 10.3889/oamjms.2018.127.
- [20] Ö. Gürlek, P. Gümüş, N. Nizam, and N. Buduneli, "Coronally advanced flap with connective tissue graft or xenogeneic acellular dermal matrix in the treatment of multiple gingival recessions: A split-mouth randomized clinical trial," *J. Esthet. Restor. Dent.*, vol. 32, no. 4, pp. 380–388, Jun. 2020, doi: 10.1111/jerd.12547.
- [21] A. M. Pabst, K. M. Lehmann, C. Walter, M. Krüger, S. I. Stratul, and A. Kasaj, "Influence of porcine-derived collagen matrix on endothelial progenitor cells: an in vitro study," *Odontology*, vol. 104, no. 1, pp. 19–26, Jan. 2016, doi: 10.1007/s10266-014-0186-x.
- [22] S. Blatt *et al.*, "Biofunctionalization of porcine-derived collagen matrices with platelet rich fibrin: influence on angiogenesis in vitro and in vivo," *Clin. Oral Investig.*, vol. 24, no. 10, pp. 3425–3436, Oct. 2020, doi: 10.1007/s00784-020-03213-8.
- [23] C. M. Schmitt *et al.*, "Soft tissue volume alterations after connective tissue grafting at teeth: The subepithelial autologous connective tissue graft versus a porcine collagen matrix - A pre-clinical volumetric analysis," *J. Clin. Periodontol.*, vol. 43, no. 7, pp. 609–617, Jul. 2016, doi: 10.1111/jcpe.12547.
- [24] R. Cosgarea, R. Miron, R. Bora, A. Rosu, S. Buduru, and A. Sculean, "Long-term results after treatment of multiple adjacent gingival recessions with the modified coronally advanced tunnel and a porcine acellular dermal matrix," *Quintessence Int. (Berl)*, vol. 52, no. 1, pp. 32–44, Jan. 2021, doi: 10.3290/j.qi.a45171.
- [25] M. Stefanini, A. Rendon, and G. Zucchelli, "Porcine-Derived Acellular Dermal Matrix for Buccal Soft Tissue

- Augmentation at Single Implant Sites: A 1-Year Follow-up Case Series," *Int. J. Periodontics Restorative Dent.*, vol. 40, no. 1, pp. 121–128, Jan. 2020, doi: 10.11607/prd.4477.
- [26] F. Brugnamì, A. Caiazzo, and P. Mehra, "Tunnel Regenerative Corticotomy (TURC): A modified approach in surgically-assisted orthodontics," *J. Oral Biol. Craniofacial Res.*, vol. 11, no. 1, pp. 63–65, Jan. 2021, doi: 10.1016/j.jobcr.2020.11.017.
- [27] F. R. Kloss, V. Offermanns, P. Donkiewicz, and A. Kloss-Brandstätter, "Customized allogeneic bone grafts for maxillary horizontal augmentation: A 5-year follow-up radiographic and histologic evaluation," *Clin. Case Reports*, vol. 8, no. 5, pp. 886–893, May 2020, doi: 10.1002/ccr3.2777.
- [28] M. Stefanini, D. Bianchelli, and M. Sangiorgi, "Porcine-derived acellular dermal collagen matrix and enamel matrix derivative for the treatment of infrabony defect in the esthetic area," *Plast. Aesthetic Res.*, vol. 2021, p. 15, Mar. 2021, doi: 10.20517/2347-9264.2020.186.